



# Deep Dive in Pulmonary Embolism & Deep Vein Thrombosis

By:  
Saba Lahsaei, MD FACC





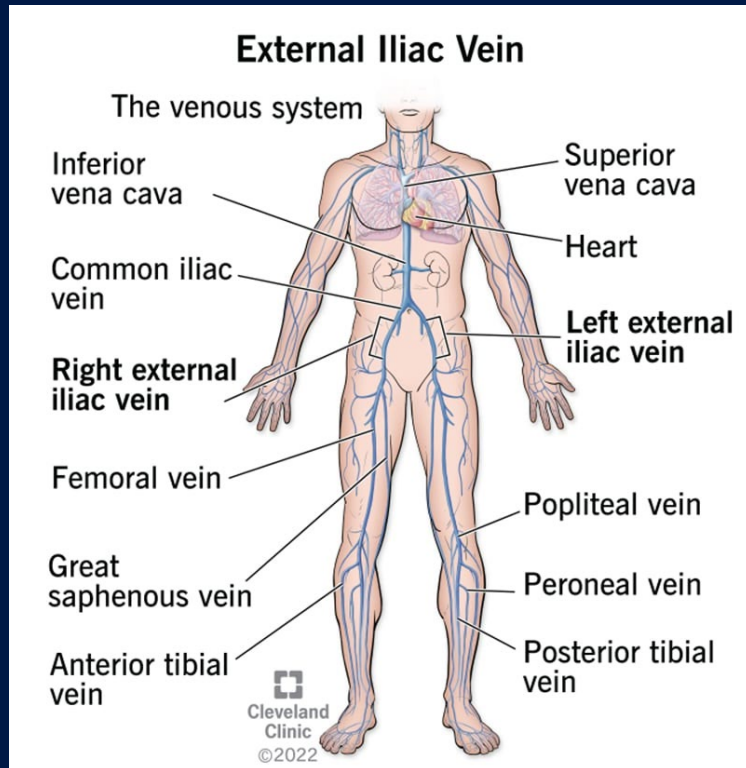
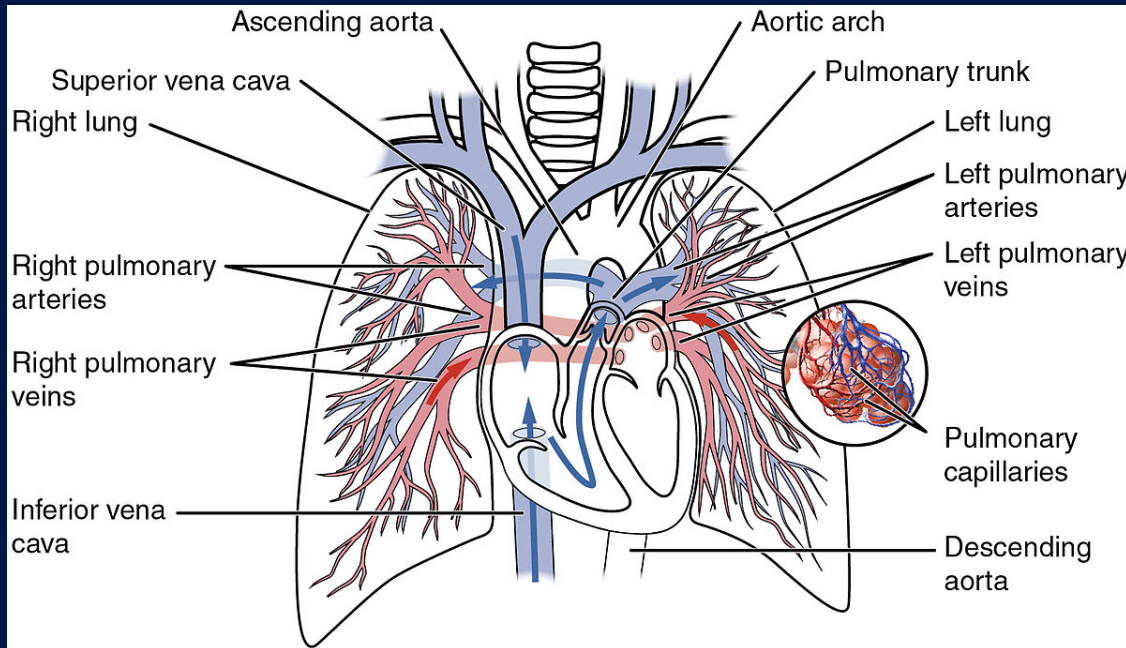
**Conflict of interest: None**



# Content:

- Overview of pulmonary and venous anatomy
- Prevalence
- Etiology
- Risk factors
- Clinical Presentation
- Diagnosis
- Management
- Cases

# Anatomy



# Prevalence

VTE (PE + DVT) 900,000/ye in US



PE hospitalization 150,000-200,000/yr



PE death 100,000-200,000/yr



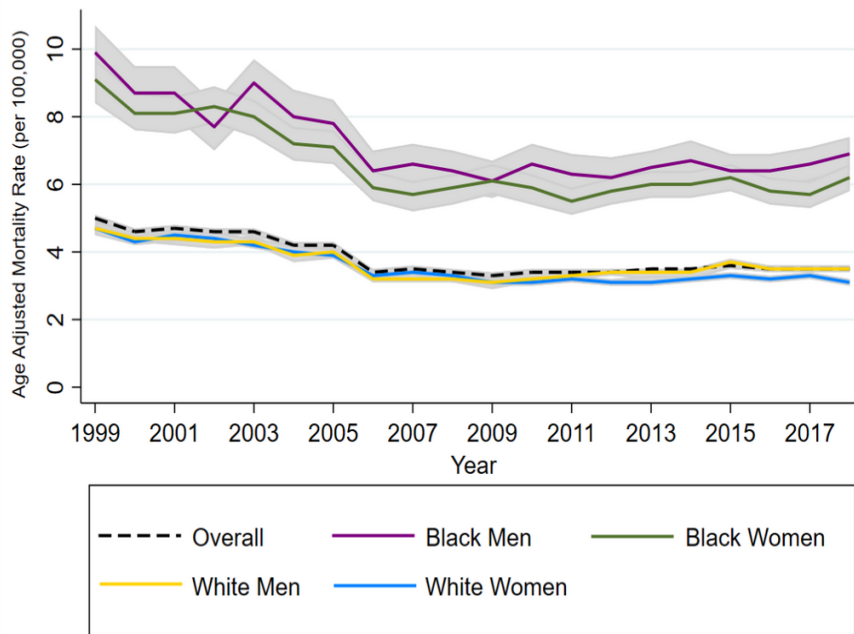
PE sequela 50%



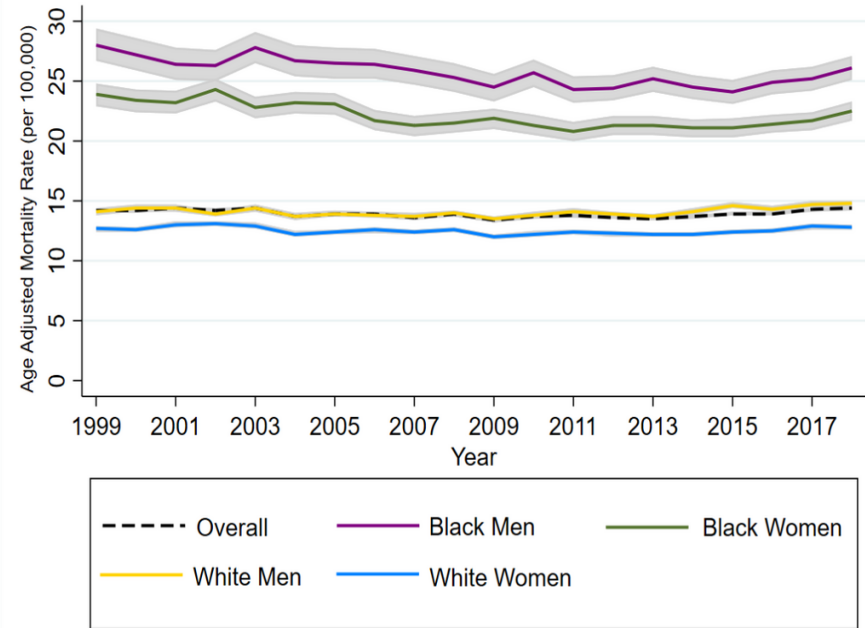
CTEPH 4%

# Mortality

**A** PE as underlying cause of death



**B** PE-related death (underlying and contributing causes of death)

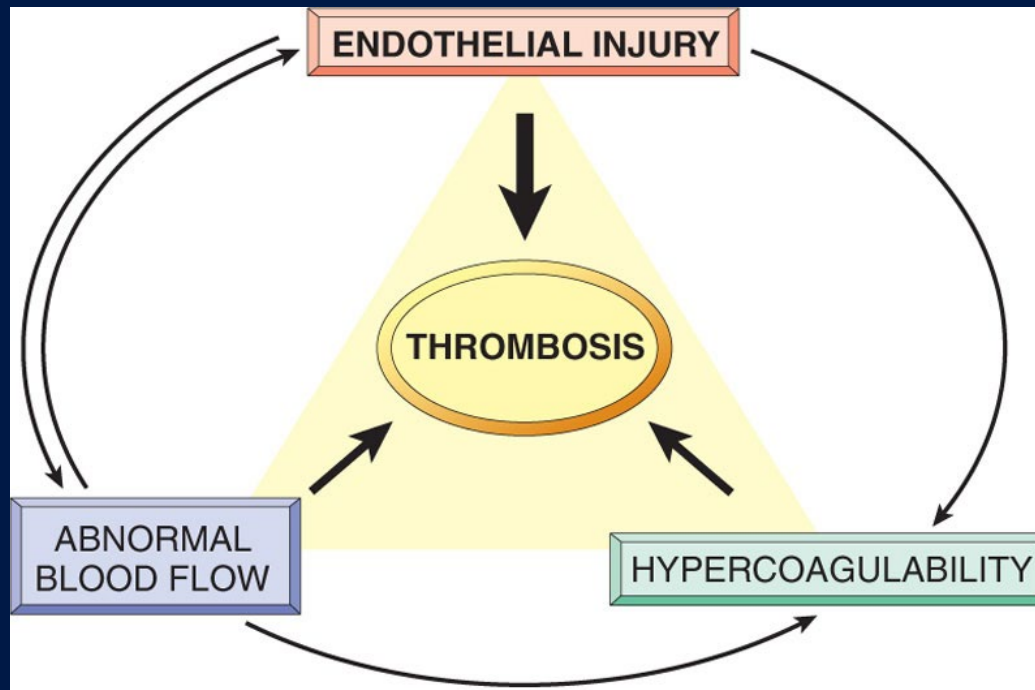


- If left untreated, mortality as high as 30%
- Overall death rate even when treated up to 8%
- Pulmonary Embolism is #3 cause of CV death after MI and CVA

# Etiology

- Pulmonary embolism is caused by occlusion of pulmonary arteries
  - Results from Clots broken off from DVTs.

## Virchow's Triad



# Sources

- Deep vein thrombosis (Most common)
- Infectious Endocarditis of right side heart
- Air Embolism
- Fat embolism
- Amniotic fluid embolism
- Septic embolism
- Tumor Embolism



# Risk Factors

Major Risk Factors	Minor Risk Factors
Post op State: Major abdominal/pelvic surgery, Hip/knee replacement, Postop ICU	Cardiovascular: Congenital heart disease, heart failure, HTN, Superficial venous thrombosis, central venous catheters
Obstetrics: Late pregnancy, C-section, Puerperium	Humoral: Estrogen use, OCP, Hormone replacement
Lower limb affections: Fractures, Extensive varicosities	Miscellaneous: COPD, neurological impairment, latent malignancy, long-distance travel in the sitting position, obesity
Malignancies: Abdominal/pelvic, advanced/metastatic stage	Other: Inflammatory bowel disease, nephrotic syndrome, chronic dialysis, myeloproliferative disease, paroxysmal nocturnal hemoglobinuria
Limited mobility: Hospitalization, geriatric care	
Miscellaneous: History of previous venous thromboembolism	

# Symptoms

Pulmonary embolism	Deep vein thrombosis
Shortness of breath	Swelling
Chest pain	Pain
Syncope/Dizziness	Cramping

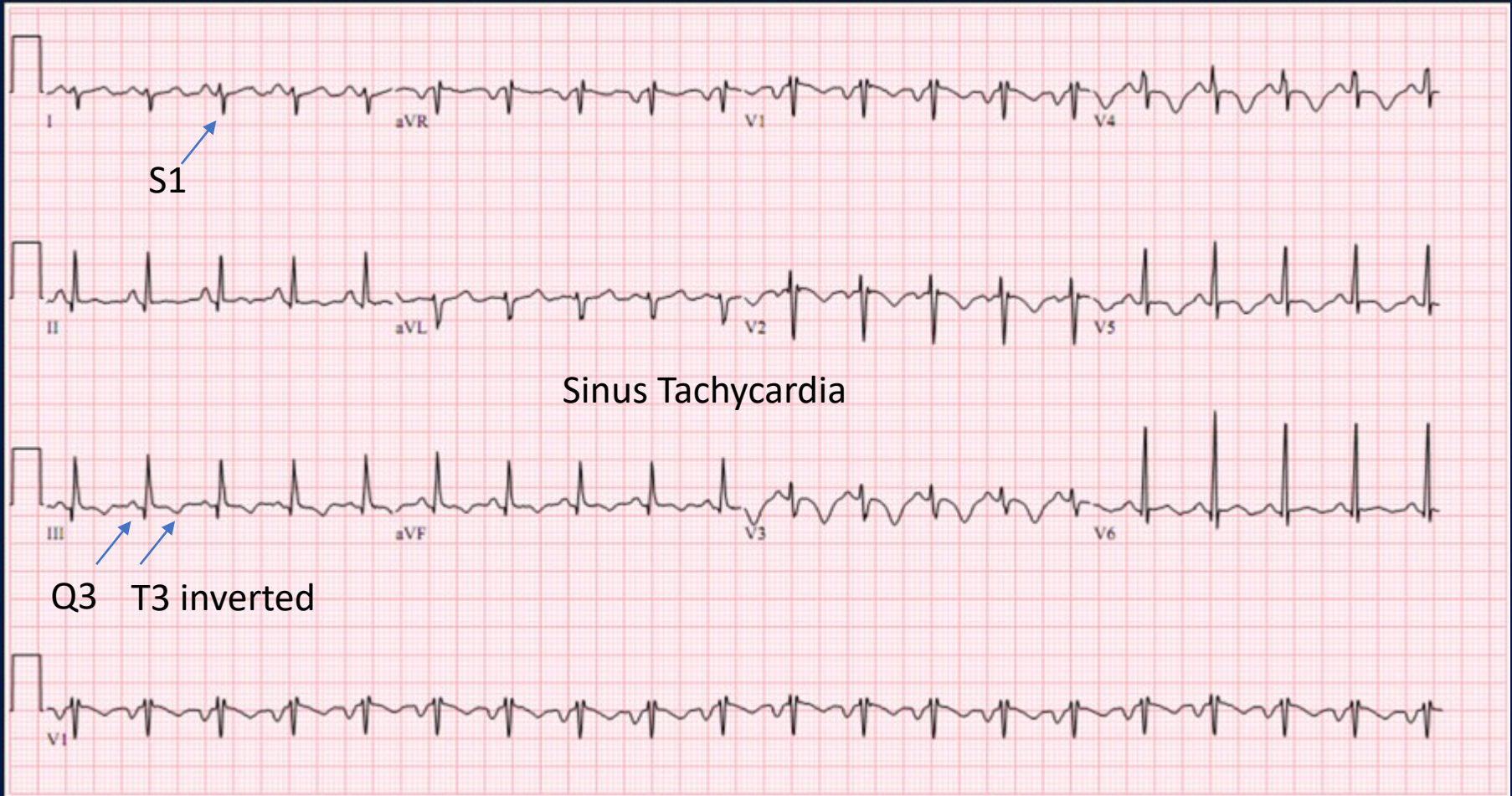
# Signs

Pulmonary embolism	Deep vein thrombosis
Tachycardia	Edema
Hypoxia	Redness
Hypotension	Tenderness

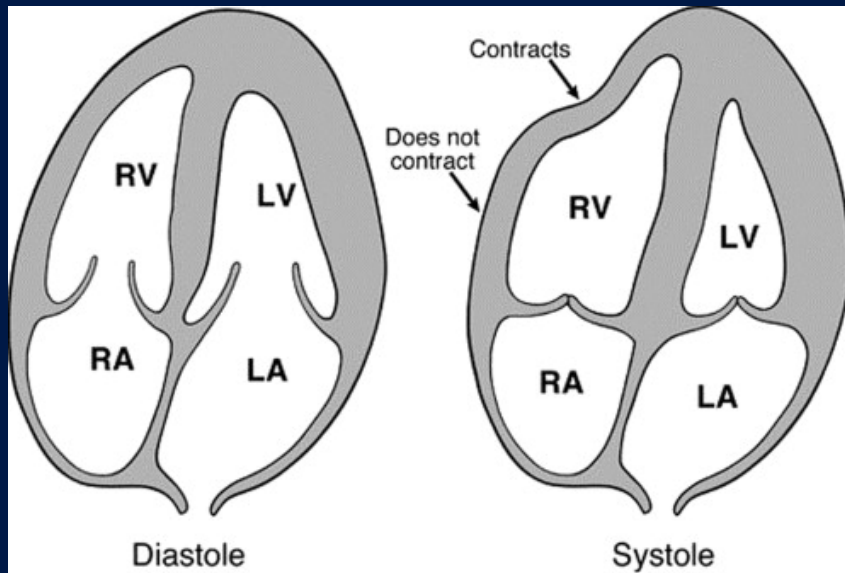
# Work Up

PE	DVT
ECG	Ultrasound
Echo	CT venous phase
CT	MRI
Angiogram	Venogram
D-Dimer	
Trop	
BNP	
ABG	

# ECG

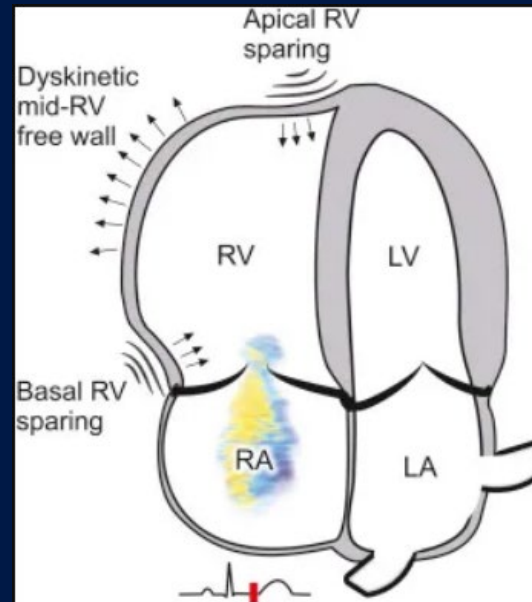


# Echo

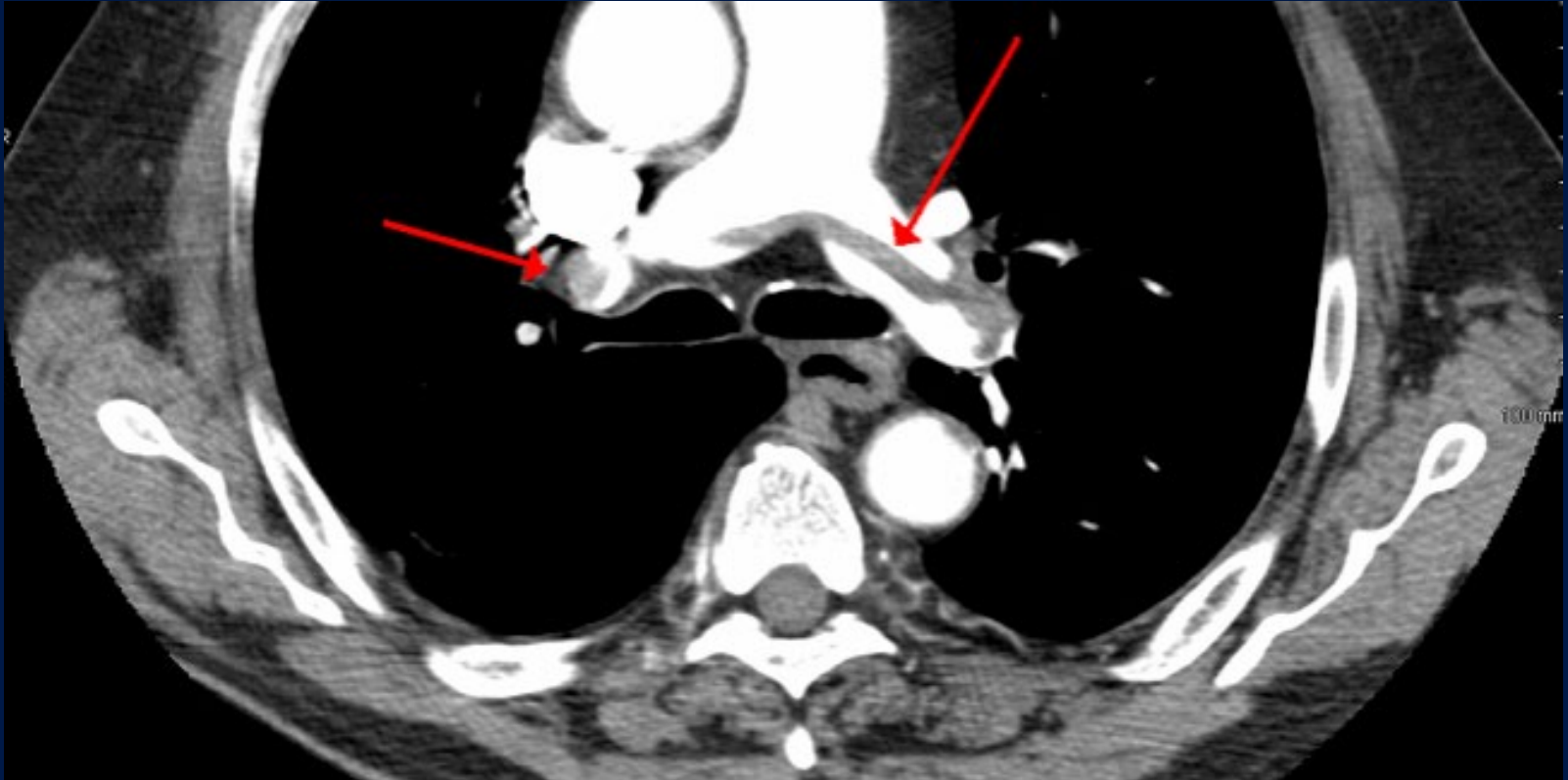


## McConnell's Sign

- Mid RV akinesia
- RV apex normal contractility
- RV dilation (RV strain)



# CT



# Assessment

- Hypotension
- Right ventricular dysfunction
- BNP
- Cardiac enzymes
- PESi or sPESI score

Predictors	Points assigned
Age > 80 years	1
History of cancer	1
History of heart failure	1
Pulse > 110 beats/min	1
Systolic blood pressure < 100 mmHg	1
Arterial oxygen saturation < 90 %	1
Low risk = total point score 0	

Predictors	Points assigned
Age, years	Age, in years
Altered mental status*	+60
Systolic blood pressure <100 mmHg	+30
History of cancer	+30
Arterial oxygen saturation <90 % <sup>‡</sup>	+20
Temp < 36 °C	+20
Respiratory rate ≥ 30/min	+20
Pulse ≥ 110/min	+20
Male sex	+10
History of heart failure	+10
History of chronic lung disease <sup>†</sup>	+10

A total point score for a given patient is obtained by summing the patient's age in years and the points for each applicable predictor. Points assignments correspond with the following risk classes: Class I (very low risk): ≤65; Class II (low risk): 65–85; Class III (intermediate risk): 86–105; Class IV (high risk): 106–125; Class V (very high risk): >125

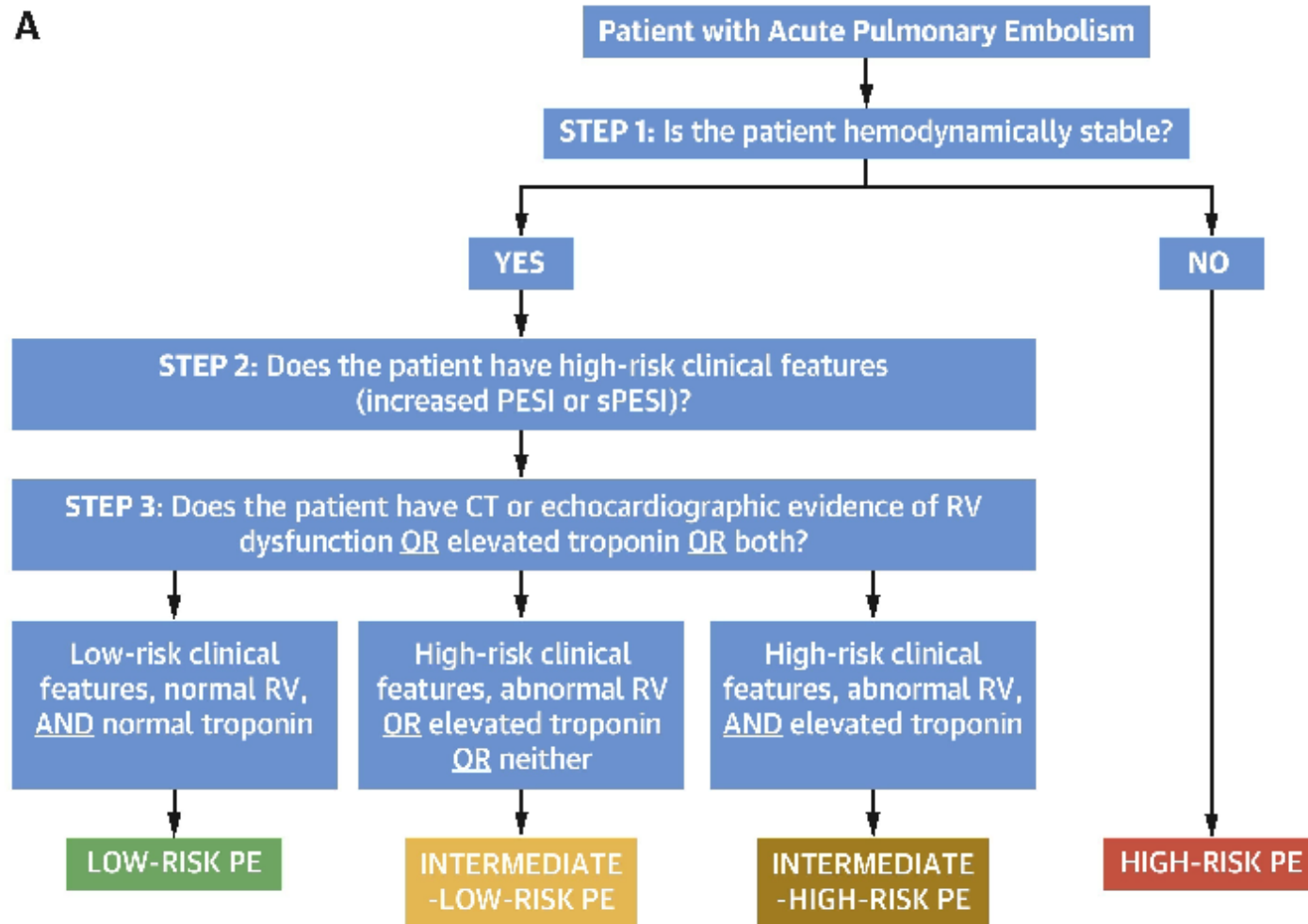
# Classification

Guidelines	Category	Hemodynamic Status	PE Severity Index (PESI) (or Simplified PESI)	Evidence of RV Dysfunction
American Heart Association (AHA, 2011)	Massive	Unstable	High	Typically Abnormal RV on Imaging, Elevated Troponin, <u>OR</u> Both
	Submassive	Stable	High	May Have Abnormal RV on Imaging <u>OR</u> Elevated Troponin <u>OR</u> Both
	Low Risk	Stable	Typically Low	None
European Society of Cardiology (ESC, 2019)	High Risk	Unstable	High	Typically Abnormal RV on Imaging, Elevated Troponin, <u>OR</u> Both
	Intermediate-High Risk	Stable	High	Abnormal RV on Imaging, <u>AND</u> Elevated Troponin
	Intermediate-Low Risk	Stable	High	May Have Abnormal RV on Imaging <u>OR</u> Elevated Troponin But Not Both
	Low Risk	Stable	Low	None



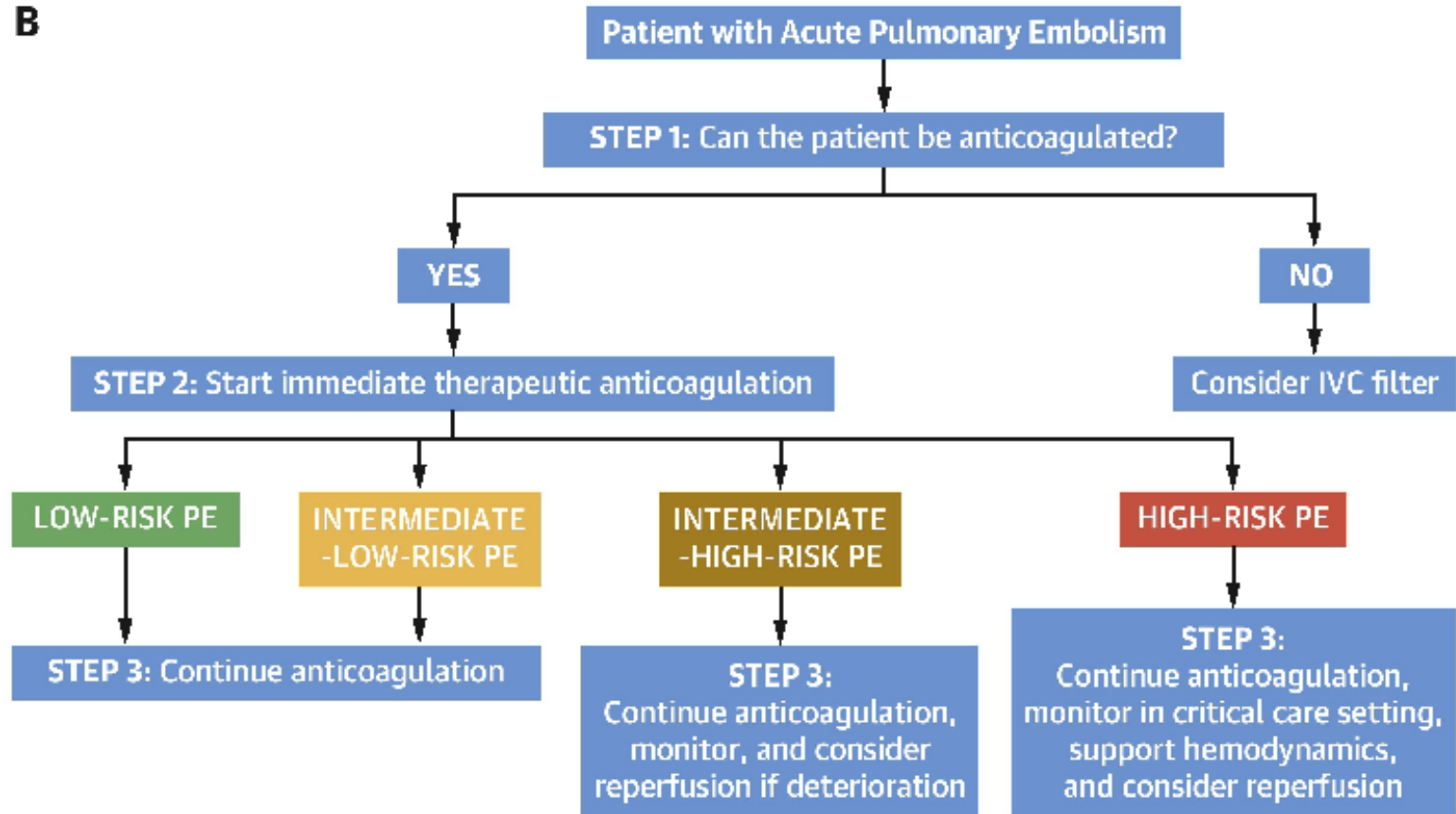
# Approach

A

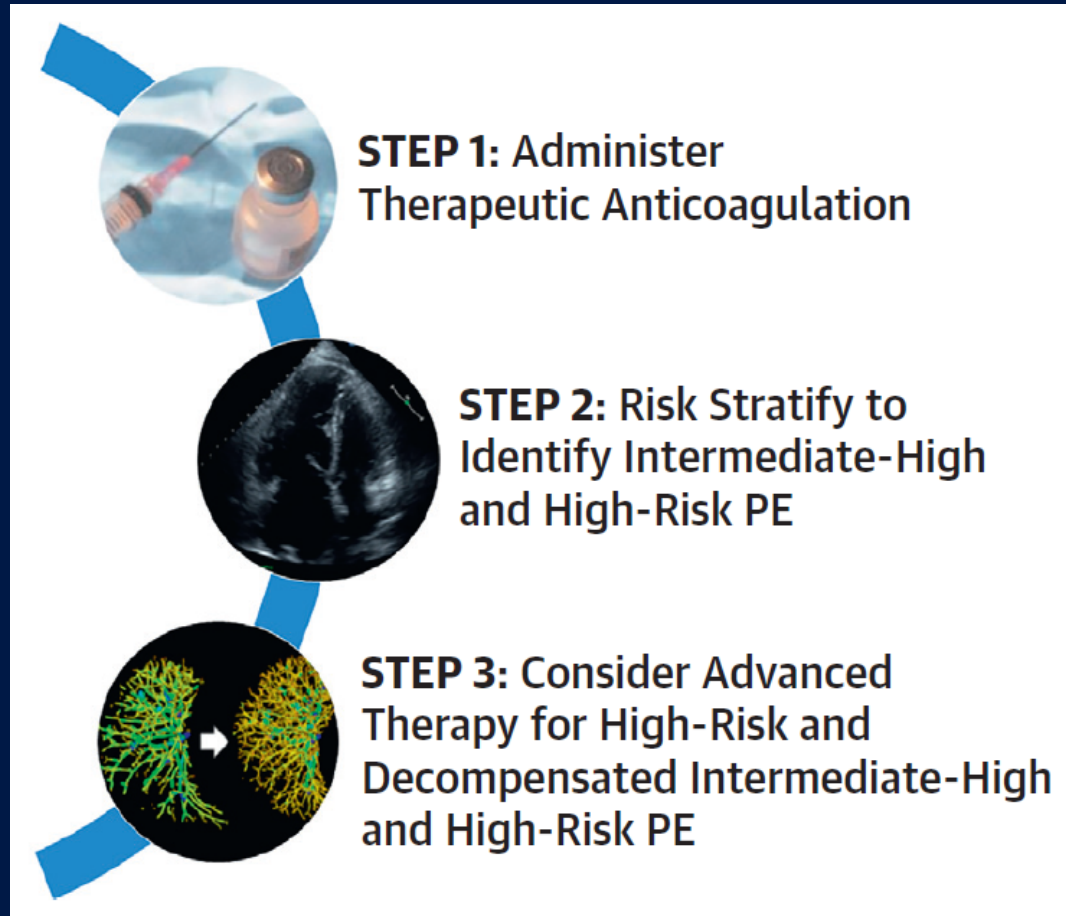


# Approach

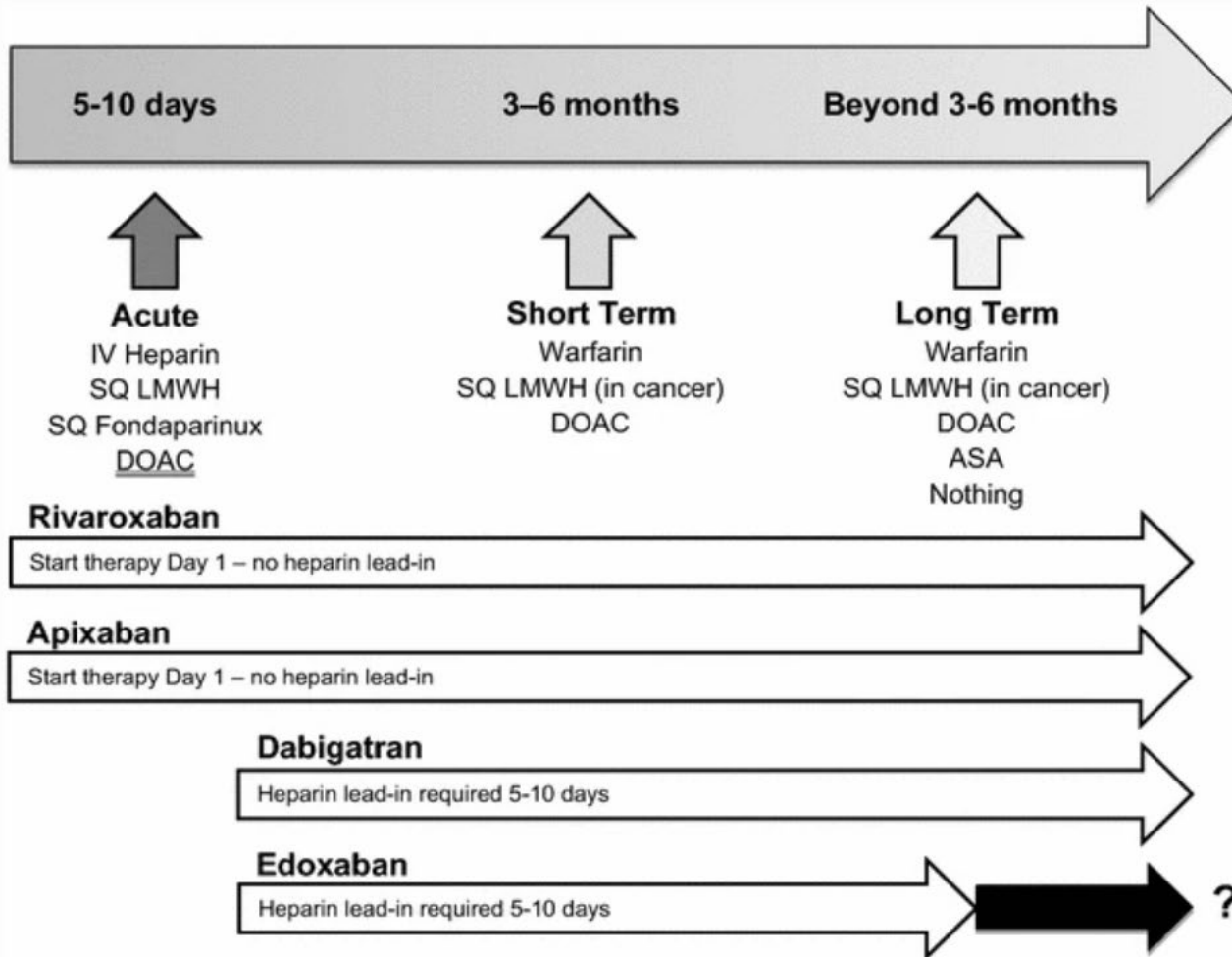
**B**



# Approach Intermediate-High or High risk



# Anticoagulation

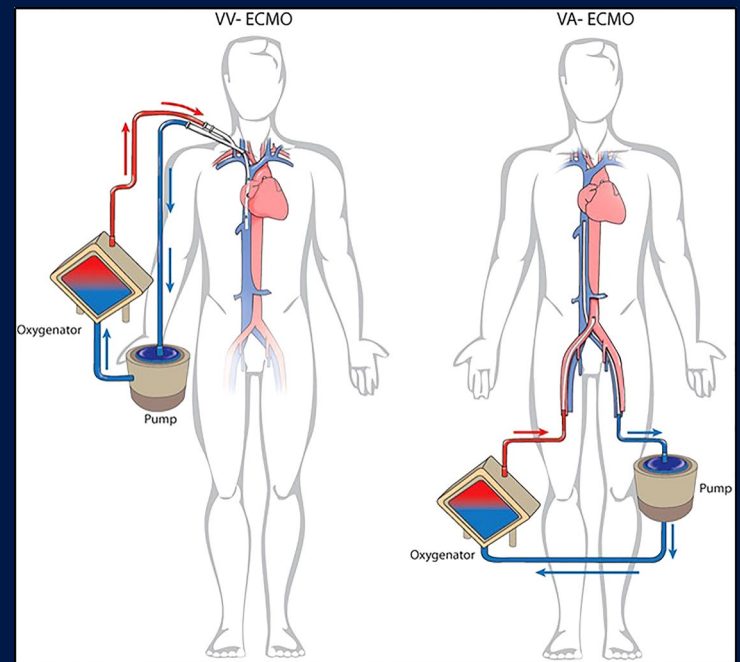
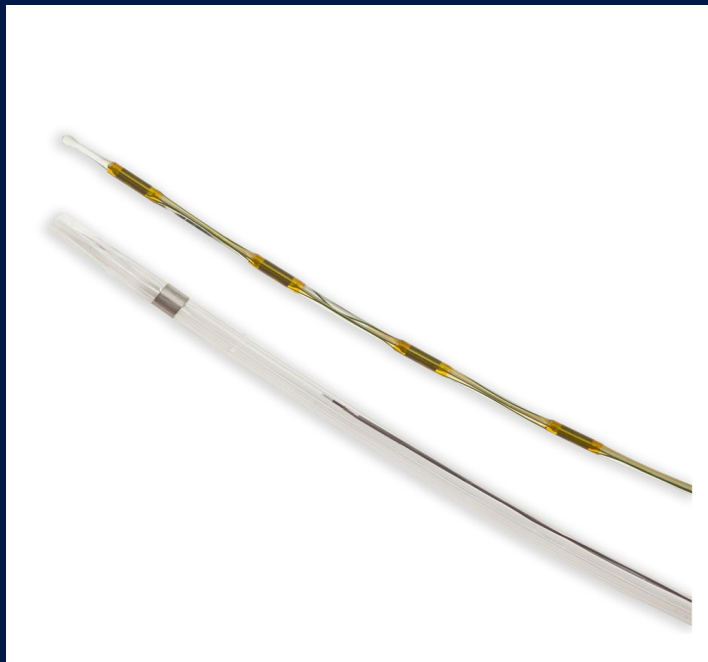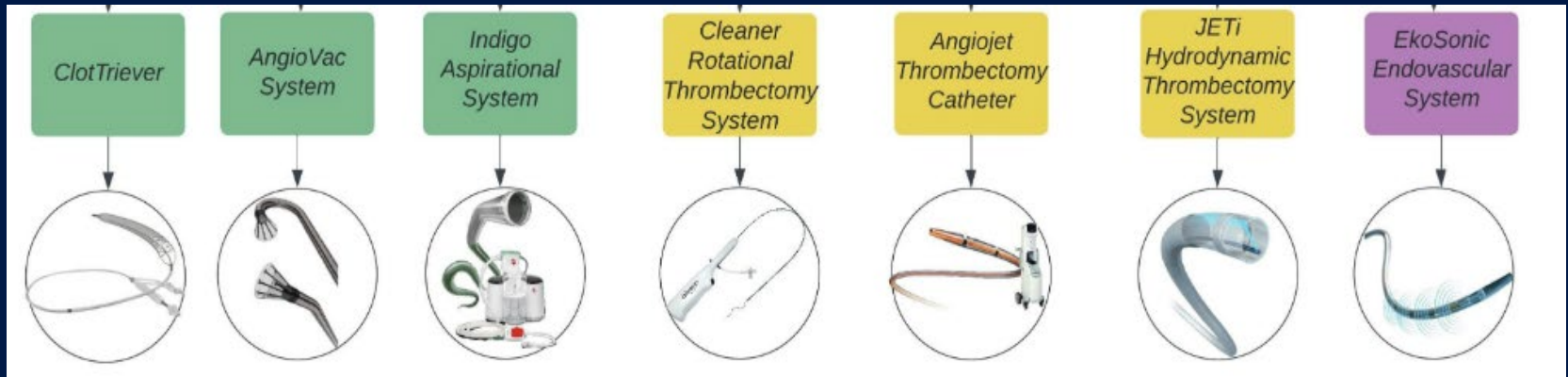


# Advanced Therapies

Option	Indications	Advantages	Disadvantages
Systemic fibrinolysis	High- and intermediate-high-risk PE	<ul style="list-style-type: none"> <li>• Rapid administration</li> <li>• Decreases mortality</li> <li>• Prevents hemodynamic collapse</li> <li>• Expedites RV recovery and symptom relief</li> </ul>	<ul style="list-style-type: none"> <li>• 2%-5% risk of ICH</li> </ul>
Catheter-directed therapy	High- and intermediate-high-risk PE	<ul style="list-style-type: none"> <li>• Expedites RV recovery and symptom relief</li> <li>• Reduced risk of ICH</li> <li>• Option for mechanical embolectomy with some devices</li> </ul>	<ul style="list-style-type: none"> <li>• Limited long-term and comparative data</li> <li>• May take time to mobilize</li> </ul>
Surgical embolectomy	High- and intermediate-high-risk PE	<ul style="list-style-type: none"> <li>• Expedites RV recovery and symptom relief</li> <li>• Reduced risk of ICH</li> <li>• Avoids need for fibrinolysis</li> </ul>	<ul style="list-style-type: none"> <li>• Limited long-term and comparative data</li> <li>• May take time to mobilize</li> <li>• Limited to more centrally located PE</li> </ul>
ECMO	Refractory cardiogenic shock	<ul style="list-style-type: none"> <li>• Supports hemodynamics and oxygenation in patients with refractory shock or hypoxemia</li> </ul>	<ul style="list-style-type: none"> <li>• Limited long-term and comparative data</li> <li>• May take time to mobilize</li> </ul>

ECMO = extracorporeal membrane oxygenation; ICH = intracranial hemorrhage; PE = pulmonary embolism; RV = right ventricular.

# Advanced Therapies



# PERT (Pulmonary Embolism Response Team)

## VTE Team (VenoThromboEmbolism Team)

